FQE IPA 1 - Rad

Radiography and imaging sciences (Kenya Medical Training College)

Scan to open on Studocu

Studocu is not sponsored or endorsed by any college or university
Downloaded by Patrick Ngobiro (pngobiro@gmail.com)

KENYA MEDICAL TRAINING COLLEGE
FACULTY OF DIAGNOSTIC SCIENCES
DEPARTMENT OF RADIOGRAPHY AND IMAGING

FINAL QUALIFYING EXAMINATION
FOR
DIPLOMA IN MEDICAL IMAGING SCIENCES

PAPER: IMAGE PATTERN ANALYSIS (IPA)

DATE: 1st February 2021	**TIME: 3 HOURS (2:00PM – 5:00 PM)**

INSTRUCTIONS

1. Attempt **ALL** Questions
2. Write the **EXAMINATION NUMBER** given on all the answer sheets provided and on the question paper.
3. Ensure that all examination answer scripts are handed in at the end of the examination
4. Ensure you sign the examination register provided

EXAMINATION NUMBER ……

This document is available on studocu

Downloaded by Patrick Ngobiro (pngobiro@gmail.com)

1. With reference to **image 1**
   a. *Name the projection* **(1 mark)**
   b. *Give 4 reasons for answer provided in (a) above based on the radiographic evidence on the image* **(2 marks)**
   c. *Label the structures A-J on radiograph 1 (***5 marks***).*
   d. *Using the radiograph, illustrate the steps involved in deriving the cardiothoracic ratio (actual calculation from image necessary)* **(2 marks***)*

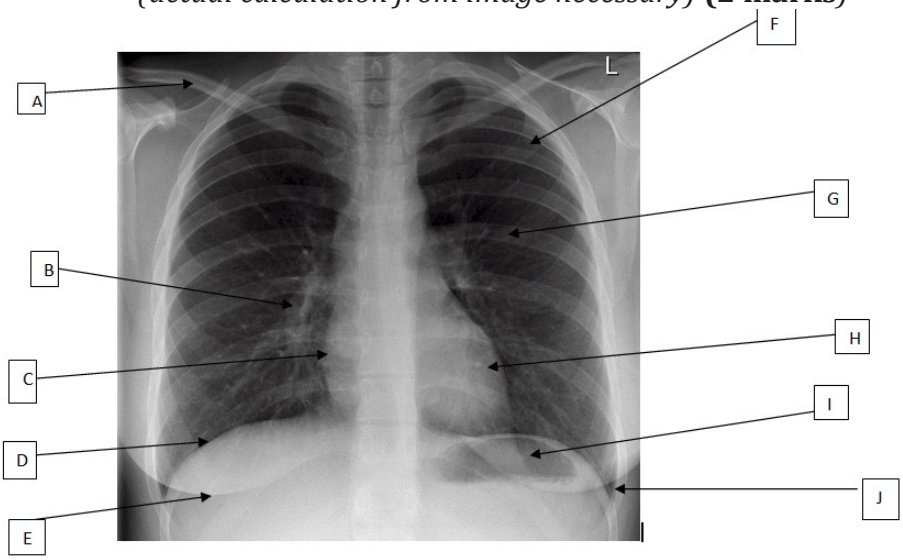

Image 1

Downloaded by Patrick Ngobiro (pngobiro@gmail.com)

2. With reference to **Image 2**
   a. Identify the projection demonstrated **(1 mark)**
   b. Give reason for answer provided above in 'a' **(1 mark)**
   c. State the **most appropriate** projections to demonstrate incidental finding indicated by "D" **(1 mark)**
   d. Name the structures labeled A to J on the radiograph **(5 marks)**
   e. Draft a radiological report and give your impression **(2 marks)**

Image 2

This document is available on studocu

Downloaded by Patrick Ngobiro (pngobiro@gmail.com)

3. With reference to **Image 3**
   a. Identify the projection demonstrated and name the **most appropriate** patient position preferred for such a case **(2 marks)**
   b. Name the structures labeled A to J on the radiograph **(5 marks)**
   c. Draft a radiological report and give your impression **(3 marks)**

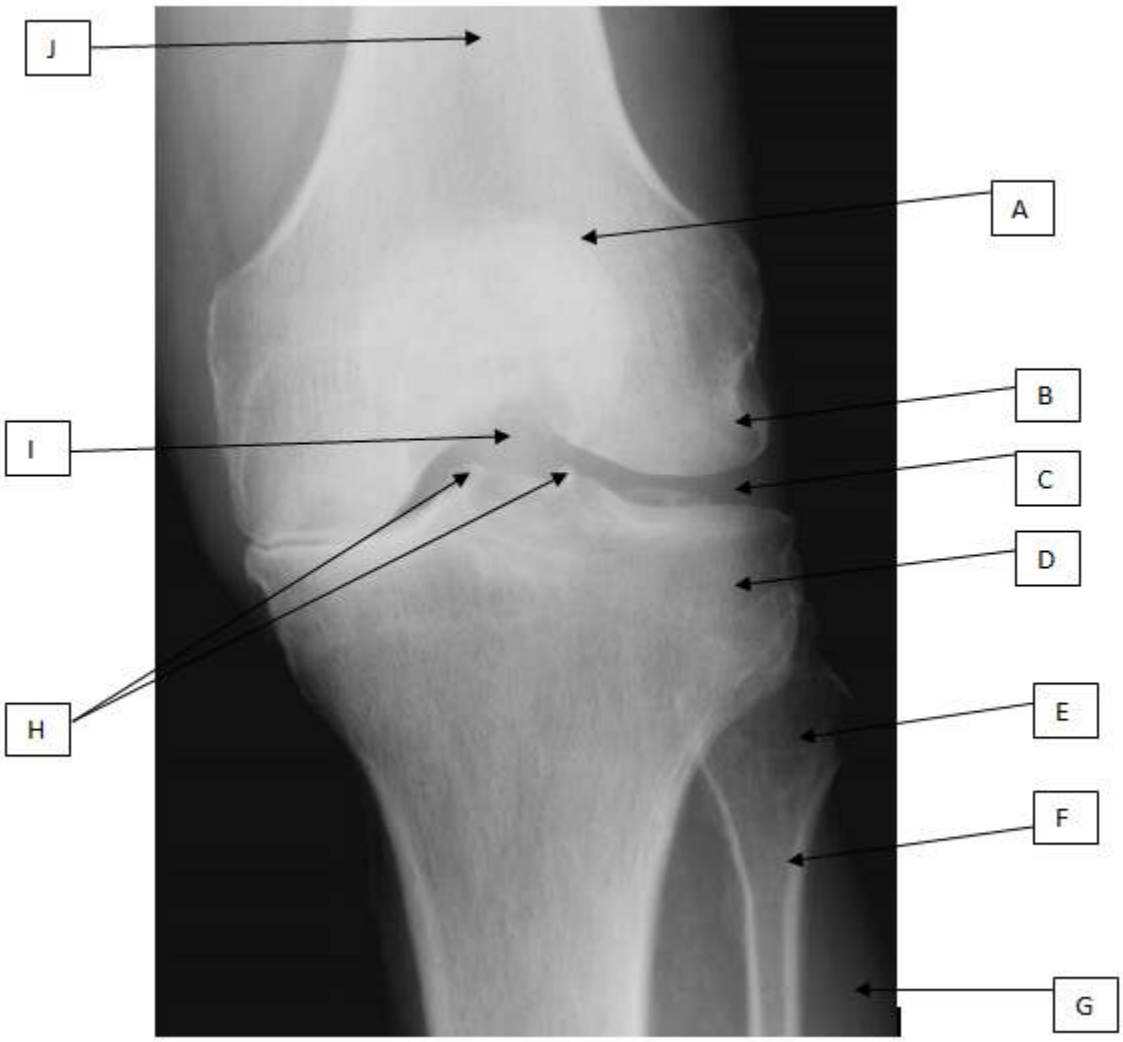

Image 3

Downloaded by Patrick Ngobiro (pngobiro@gmail.com)

4. With reference to **Image 4**
   a. Identify the projections demonstrated **(1 mark)**
   b. State the **most appropriate** projection to demonstrate structure "F" **(1 mark)**
   c. Name the structures labeled A to J on the radiogrph **(5 marks)**
   d. Draft a radiological report and give your impression **(3 marks)**

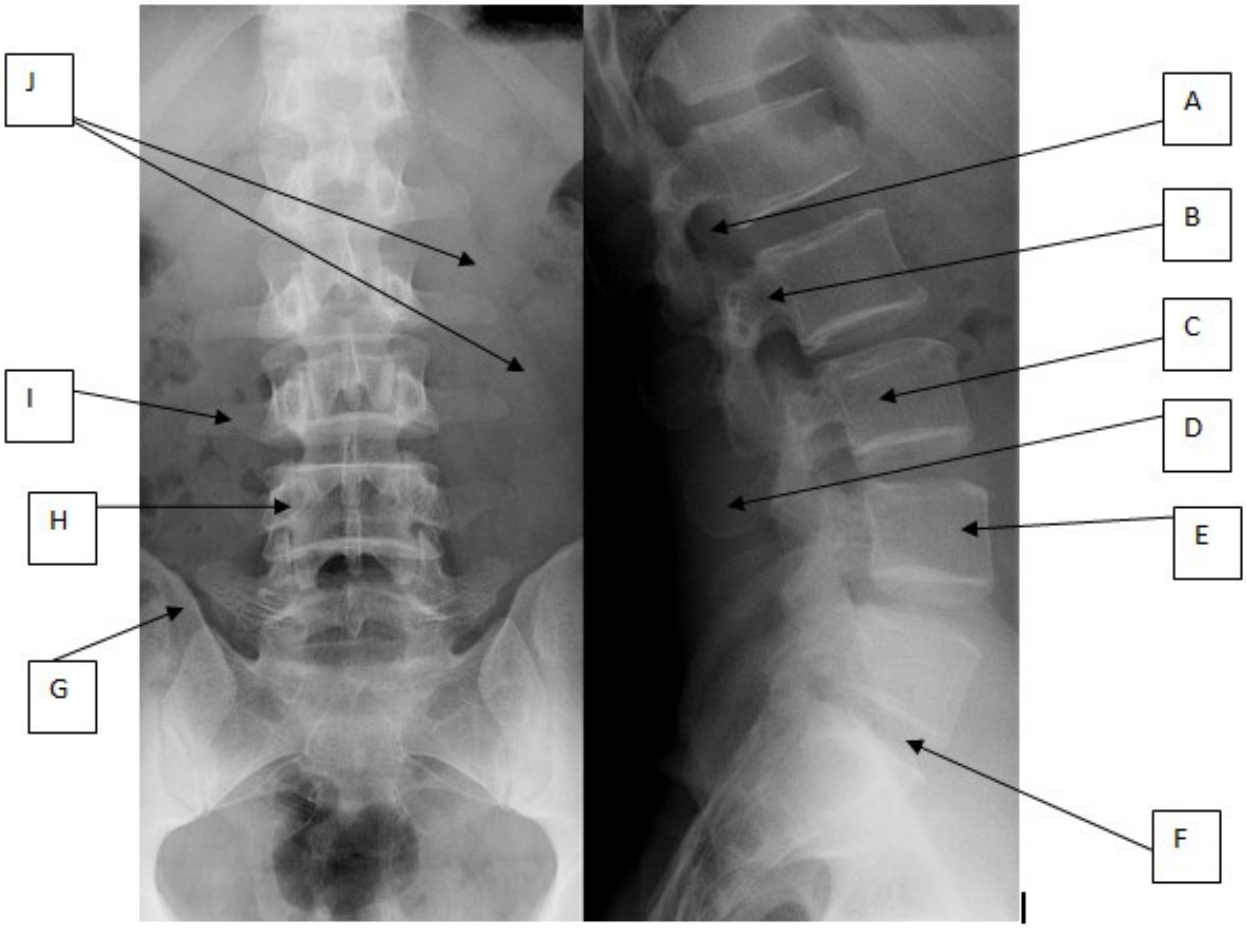

Image 4

This document is available on studocu

Downloaded by Patrick Ngobiro (pngobiro@gmail.com)

5. With reference to **Image 5**
   a. Identify the projection demonstrated **(1 mark)**
   b. provide reason for answer given above in 'a' **(2 marks)**
   c. State the **most appropriate** projection to demonstrate part "B" **(2 marks)**
   d. Name the structures labeled A to J on the radiograph **(5 marks)**

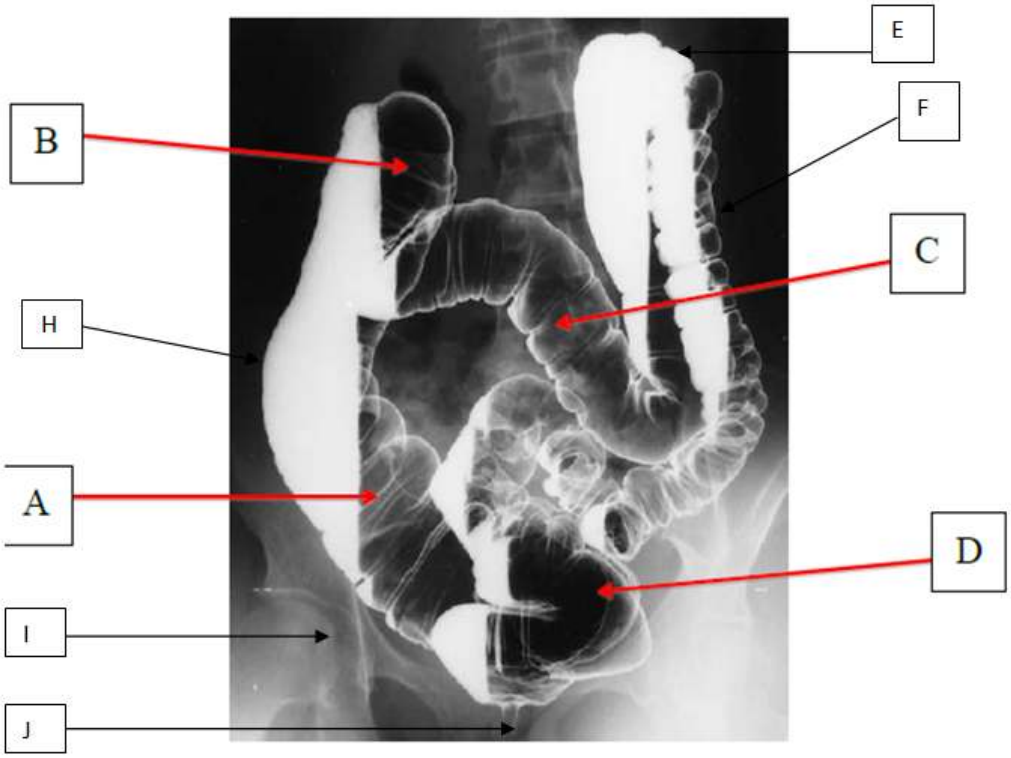

Image 5

Downloaded by Patrick Ngobiro (pngobiro@gmail.com)

6. With reference to **Image 6**
   a) Identify the procedure and projection demonstrated **(2 marks)**
   b) Give reason for answer provided above in 'a' **(3 marks)**
   c) Name the structures labeled A to J on the radiograph **(5 marks)**

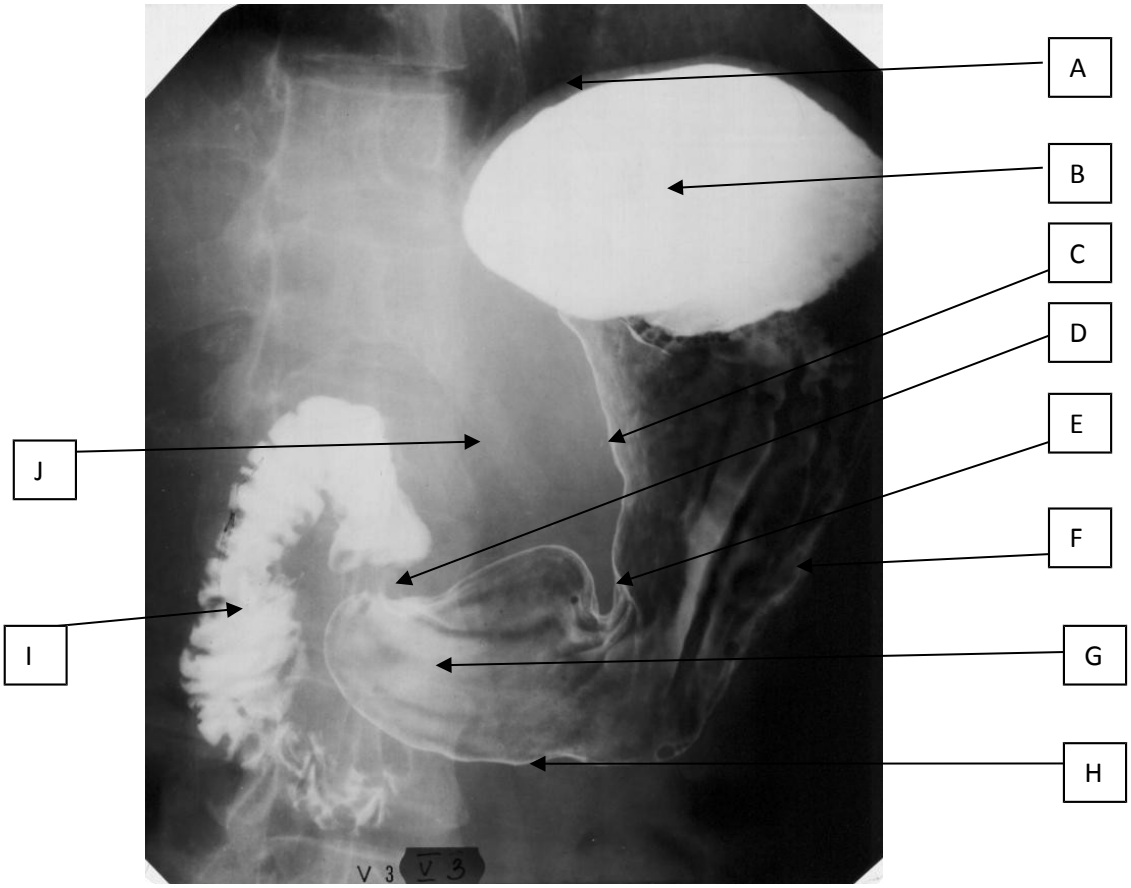

Image 6

This document is available on studocu

Downloaded by Patrick Ngobiro (pngobiro@gmail.com)

7. With reference to Image 7 the white represents injected intraluminal contrast material;
   a. Identify the procedure demonstrated **(1 mark)**
   b. State the **most preferred** imaging modality to demonstrate structure "B" **(1 mark)**
   c. Name the structures label A to E on the radiograph **(5 marks)**
   d. Trace the path the contrast medium took from the point of injection **(3 marks)**

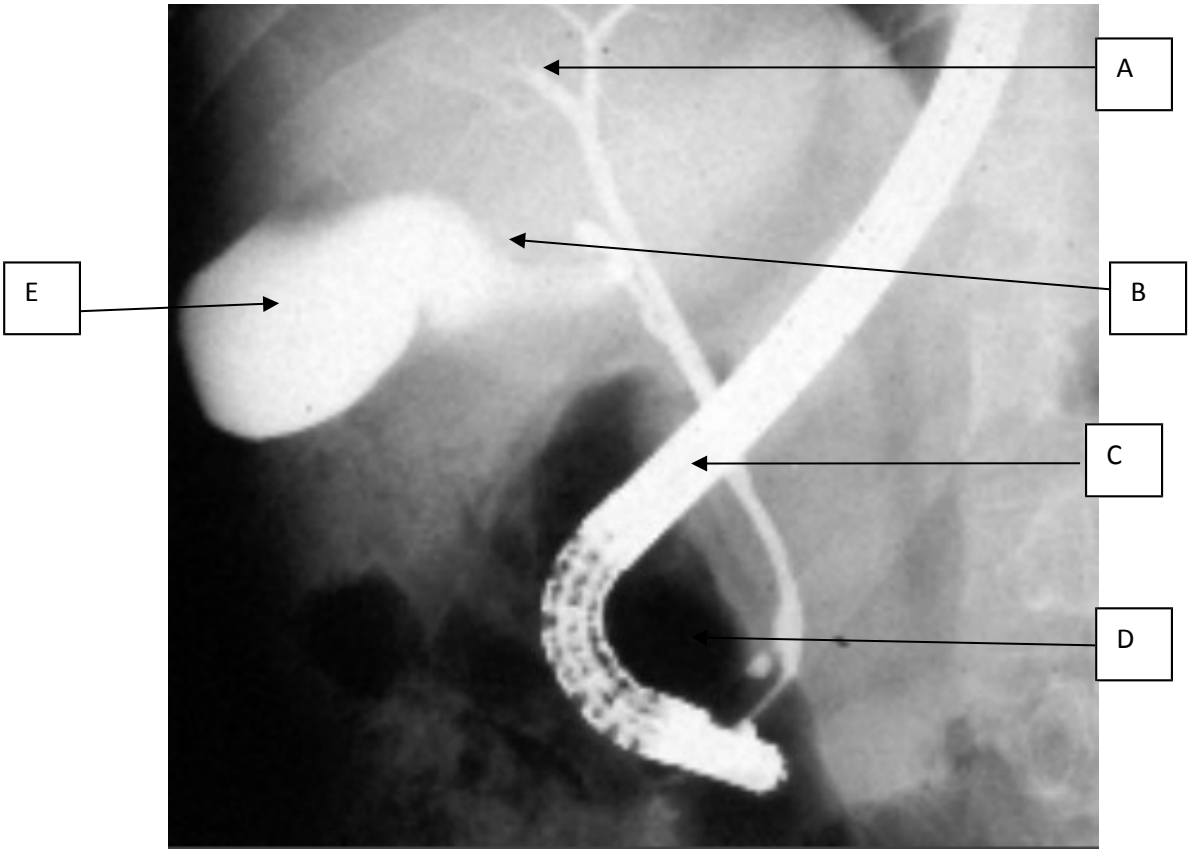

Image 7

Downloaded by Patrick Ngobiro (pngobiro@gmail.com)

8. With reference to **Image 8**
   a. Identify the contrast media procedure demonstrated **(2 marks)**
   b. State the **most appropriate** modality to demonstrate part "E" **(1 mark)**
   c. Name the structures label A to G on the radiograph **(7 marks)**

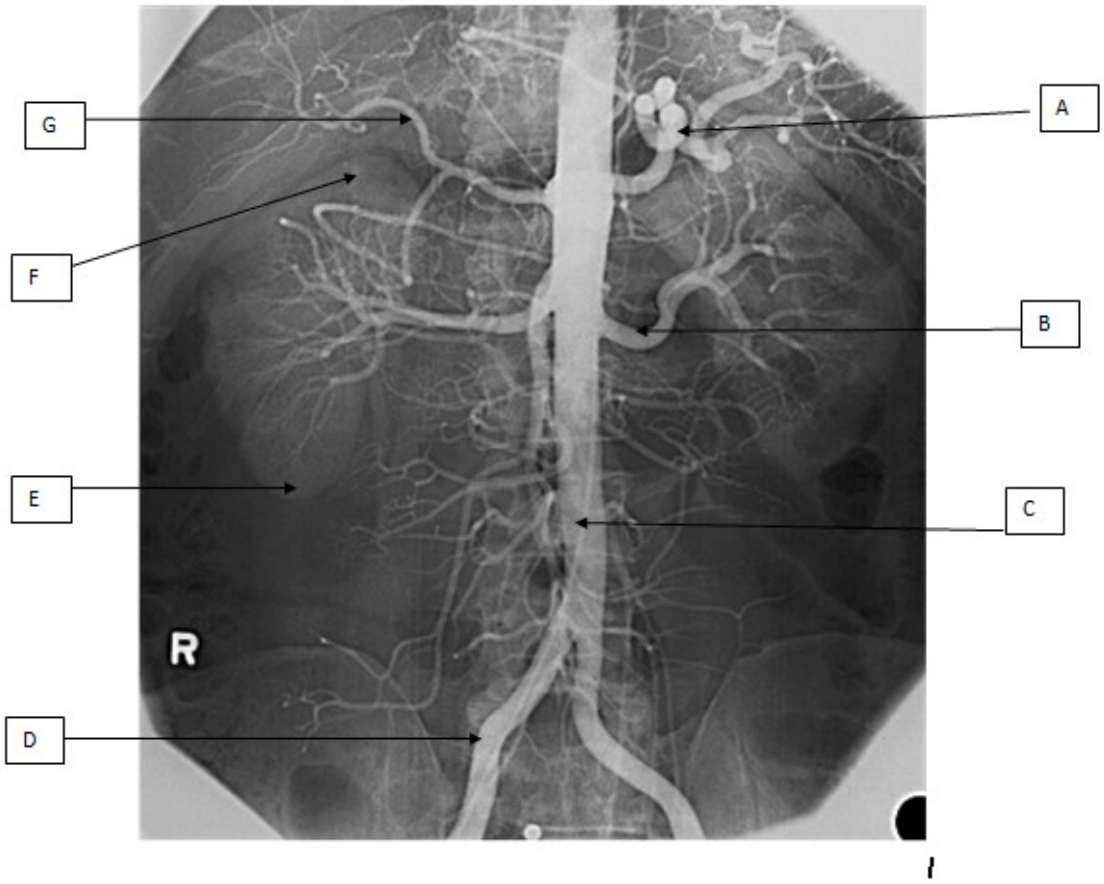

Image 8

This document is available on studocu

Downloaded by Patrick Ngobiro (pngobiro@gmail.com)

9. With reference to **Image 9**
   a. Identify the modality demonstrated **(1 mark)**
   b. Name the plane and imaging window displayed **(1 mark)**
   c. Identify the scanning phase most likely when the image was taken and give reason **(2 marks)**
   d. Which level is this cross section taken from (A, B C or D)? Give two (2) reasons (**3 marks**)
   e. Name the structures labeled A to C on the radiograph **(3 marks)**

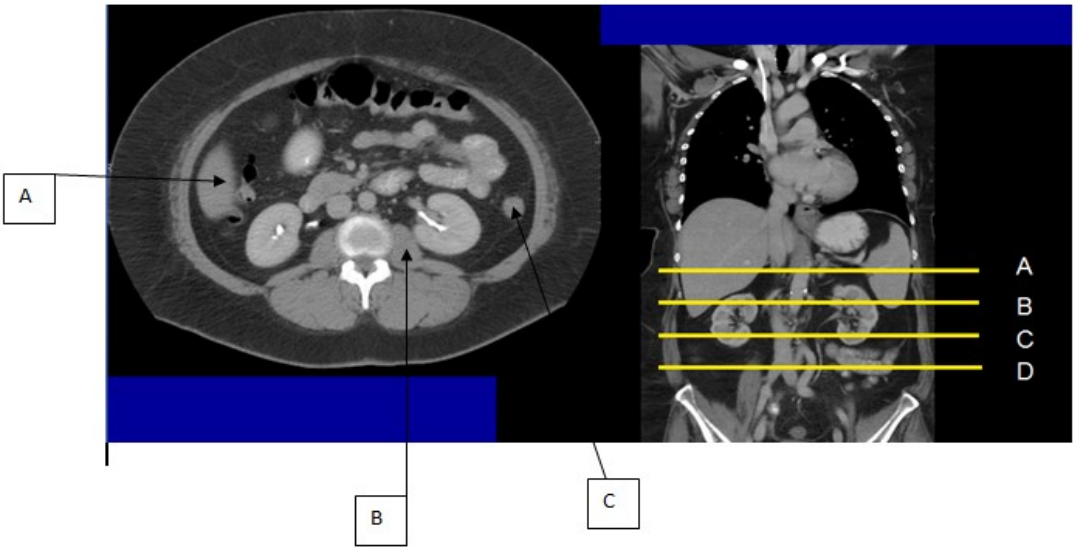

Image 9

Downloaded by Patrick Ngobiro (pngobiro@gmail.com)

10. Describe in systematic manner an approach of how to read a chest radiograph (**10 marks**)

This document is available on studocu

Downloaded by Patrick Ngobiro (pngobiro@gmail.com)